

# Efficacy and Safety of a New Triple-Combination Agent for the Treatment of Facial Melasma

Susan C. Taylor, MD; Helen Torok, MD; Terry Jones, MD; Nicholas Lowe, MD; Phoebe Rich, MD; Eduardo Tschen, MD; Alan Menter, MD; Leslie Baumann, MD; Joshua J. Wieder, MD; Michael M. Jarratt, MD; David Pariser, MD; Dale Martin, MD; Jonathan Weiss, MD; Joel Shavin, MD; Nini Ramirez, MD

*Treatment of melasma, a hyperpigmentation disorder, remains a challenge. The primary objective of two 8-week, multicenter, randomized, investigator-blind studies was to compare the efficacy and safety of a hydrophilic cream formulation containing tretinoin 0.05%, hydroquinone 4.0%, and fluocinolone acetonide 0.01% (RA+HQ+FA) with the dual-combination agents tretinoin plus hydroquinone (RA+HQ), tretinoin plus fluocinolone acetonide (RA+FA),*

*and hydroquinone plus fluocinolone acetonide (HQ+FA). All agents had the same drug concentration and vehicle. A total of 641 adult patients, predominantly female, with moderate to severe melasma and Fitzpatrick skin types I through IV, were randomized to the various treatment groups. Due to the similarity of the study designs, the results of the 2 studies were combined and are reported here. The primary efficacy analysis involved the proportion of intent-to-treat patients in each treatment group whose condition had completely cleared by week 8. The results of the combined clinical trials demonstrated that significantly more of the patients treated with RA+HQ+FA (26.1%) experienced complete clearing compared with the other treatment groups (4.6%) at the end of week 8 ( $P < .0001$ ). In addition, at week 8, a 75% reduction in melasma/pigmentation was observed in more than 70% of patients treated with RA+HQ+FA compared with 30% in patients treated with the dual-combination agents. The most common adverse reactions seen with all treatment groups were erythema, skin peeling, burning, and/or stinging sensation. The majority of treatment-related adverse events were of mild severity.*

*Cutis.* 2003;72:67-72.

Cutaneous melasma is a relatively common dermatologic disease, occurring most commonly in Asian and Hispanic women of childbearing years.<sup>1-5</sup> Exposure to solar UV radiation is the most important environmental factor in the pathogenesis of melasma.<sup>2,3</sup>

Therapy for melasma remains a challenge. Pharmacologic treatments are the mainstay.<sup>2,6,7</sup>

Accepted for publication March 17, 2003.

Dr. Taylor is from Dermatology Associates, St. Luke's-Roosevelt Hospital, New York, New York. Dr. Torok is from HMT Dermatology Associates, Inc, Medina, Ohio. Dr. Jones is from J&S Studies, Bryan, Texas. Dr. Lowe is from Clinical Research Specialists, St. John's Hospital, Santa Monica, California. Dr. Rich is from Dermatology Specialists Northwest, Portland, Oregon. Dr. Tschen is from Academic Dermatology Associates, Albuquerque, New Mexico. Dr. Menter is from Texas Dermatology Associates, Dallas, Texas. Dr. Baumann is from University of Miami, Florida. Dr. Wieder is in private practice, Los Angeles, California. Dr. Jarratt is from DermResearch, Inc, Austin, Texas. Dr. Pariser is from Eastern Virginia Medical School and Virginia Clinical Research, Inc, Norfolk. Dr. Martin is from Skin Surgery Medical Group, Inc, San Diego, California. Drs. Weiss and Shavin are from Gwinnett Clinical Research Center, Snellville, Georgia. Dr. Ramirez is from Hill Dermaceuticals, Inc, Sanford, Florida.

This article was supported by an educational grant from Galderma Laboratories, L.P. Dr. Taylor is a member of advisory boards and speaker's programs and has received a research grant from Galderma. Dr. Rich is a member of the advisory board and speaker's program for Novartis Pharmaceuticals Corporation. Dr. Menter is involved in a clinical research study for Galderma. Dr. Baumann has performed clinical trials for Hill Dermaceuticals. Dr. Weiss is a member of the speaker's program and has received research grants from Galderma. All other authors report no conflict of interest.

Reprints: Susan C. Taylor, MD, Dermatology Associates, St. Luke's-Roosevelt Hospital, 1090 Amsterdam Ave, Suite 11D, New York, NY 10025 (e-mail: staylor@slrhc.org).

Hydroquinone, azelaic acid, tretinoin, and topical corticosteroids have been used as monotherapy<sup>7-11</sup> or in various combinations.<sup>12-15</sup> Kligman and Willis<sup>15</sup> found that monotherapy with hydroquinone, tretinoin, or the topical corticosteroid dexamethasone did not produce substantial hypopigmentation within a 3-month treatment period. However, they did observe satisfactory results with a combination of tretinoin 0.1%, hydroquinone 5.0%, and dexamethasone 0.1% in a hydrophilic ointment.<sup>15</sup> Furthermore, Kligman and Willis,<sup>15</sup> as well as other researchers, have noted efficacy and safety benefits with use of hydroquinone, tretinoin, and various topical corticosteroids. In experimental and clinical studies, the use of tretinoin and other retinoids has been found to abrogate the epidermal atrophy that can occur with topical corticosteroids.<sup>16,17</sup> This could be due to the ability of tretinoin and other retinoids to induce hyperplasia of epidermal cells and to induce dermal collagen synthesis.<sup>16,17</sup> The objective of the 2 well-controlled trials featured in this article was to compare the efficacy and safety of the combination of hydroquinone, tretinoin, and the fluorinated topical corticosteroid fluocinolone acetonide, in a hydrophilic cream formulation, with 3 dual-combination products in the clearing of melasma.

## Methods

**Study Design**—The 2 pivotal trials used similar multicenter, randomized, investigator-blind, active-control, parallel-group protocols. Thirteen centers were involved in these trials. Both studies compared a triple-combination hydrophilic cream vehicle containing tretinoin 0.05%, hydroquinone 4.0%, and fluocinolone acetonide 0.01% (RA+HQ+FA) with the dual-combination products tretinoin plus hydroquinone (RA+HQ), tretinoin plus fluocinolone acetonide (RA+FA), and hydroquinone plus fluocinolone acetonide (HQ+FA). All products involved the same drug concentrations and vehicle. All formulations were used once daily at night. A total of 641 adult patients were randomized to the various treatment groups. Objective evaluation of melasma severity at baseline and at various points after treatment involved investigator assessment of global improvement from baseline using an 8-point scale (0=completely clear to 7=worse) at each follow-up visit. A baseline photograph was used for comparison.

**Patient Population**—Patients enrolled in the study were predominantly white women (aged 21 to 75 years) with Fitzpatrick skin types I through IV. For enrollment into the study, all patients had to demonstrate a stable hyperpigmentation on the face

Table 1.

### Melasma Severity Rating Scale Used in Primary and Secondary Efficacy Analysis

Score	Hyperpigmentation Status
0	Cleared: color of melasma lesions approximately equivalent to surrounding normal skin or with minimal residual hyperpigmentation
1	Mild: color slightly darker than the surrounding normal skin
2	Moderate: color moderately darker than the surrounding normal skin
3	Severe: color markedly darker than the surrounding normal skin

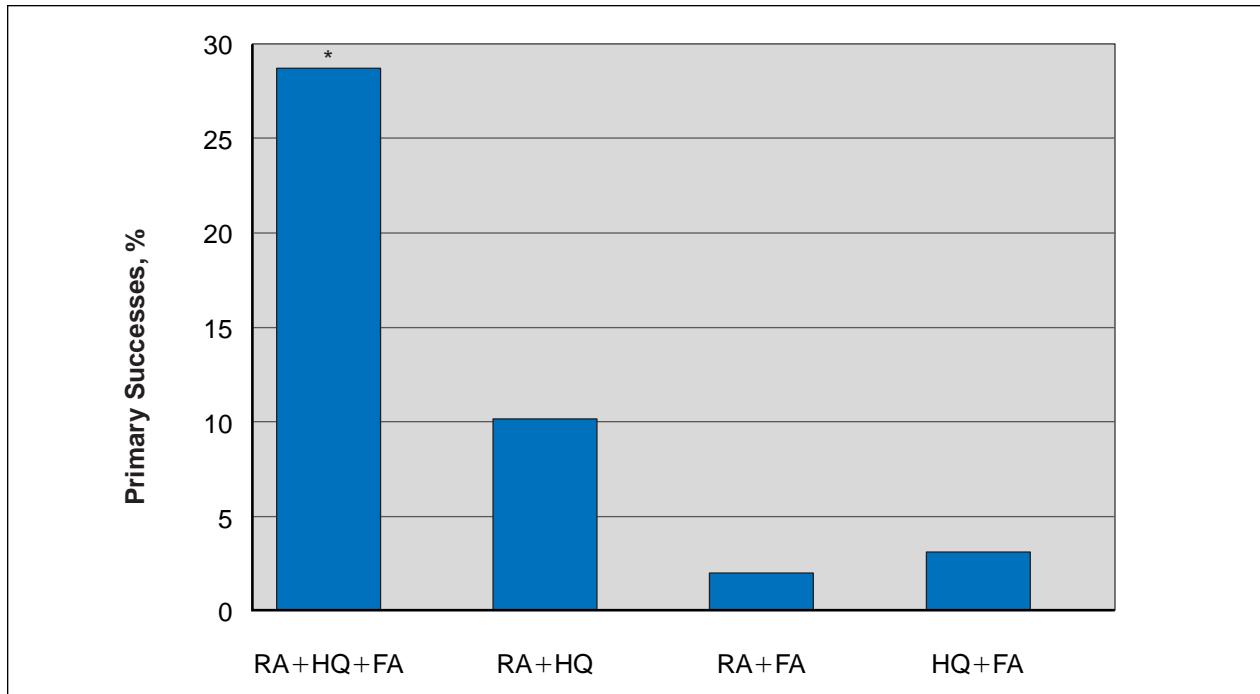
for at least 3 months' duration, macular lesions that were neither depressed nor atrophic, and melasma severity scores of at least 2 (ie, hyperpigmentation that was at least moderately darker than the surrounding normal skin). There were no significant differences in demographic parameters or skin phototypes among patients in each of the 4 treatment groups. The degree of hyperpigmentation in all patients was moderate to severe.

**Efficacy and Safety Analysis**—The primary efficacy end point involved the investigators' assessment of the proportion of intent-to-treat patients in each treatment group who achieved complete clearing at week 8. The secondary end point (secondary success) involved the proportion of intent-to-treat patients in each treatment group who achieved complete clearing (score=0) or near-complete clearing (ie, mild residual hyperpigmentation, score=1) by week 8 (Table 1).

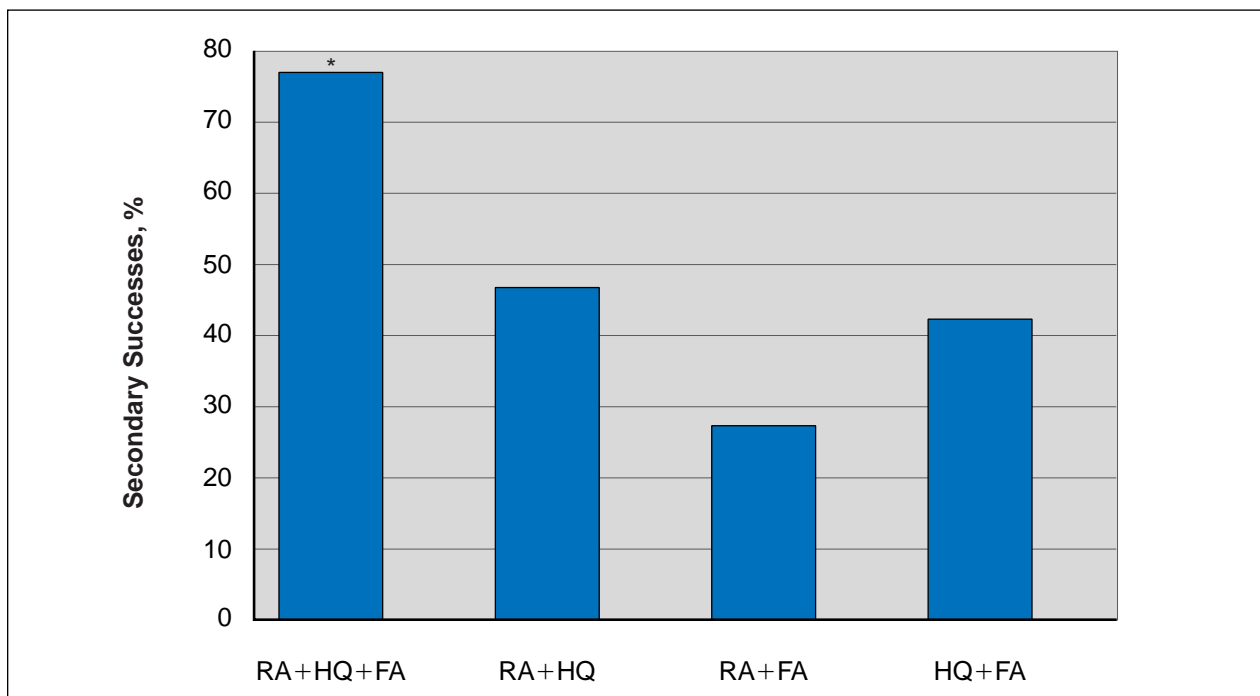
All patients randomized to the various treatment groups were analyzed for adverse events. Statistical analysis involved the Cochran-Mantel-Haenszel test, stratified by center.

## Results


**Efficacy**—Significantly more of the patients treated with RA+HQ+FA (26.1%) experienced complete clearing compared with each of the dual-therapy groups at week 8 (9.5% for RA+HQ, 1.9% for RA+FA, and 2.5% for HQ+FA,  $P<.001$ ). When



**Figure 1.** Percentage of patients who experienced complete clearing on or before day 56: intent-to-treat population comparing a hydrophilic cream formulation containing tretinoin 0.05%, hydroquinone 4.0%, and fluocinolone acetonide 0.01% (RA+HQ+FA) with the dual-combination agents tretinoin plus hydroquinone (RA+HQ), tretinoin plus fluocinolone acetonide (RA+FA), and hydroquinone plus fluocinolone acetonide (HQ+FA). Asterisk indicates  $P < .001$  vs dual-therapy combinations.



**Figure 2.** Percentage of patients who experienced complete or near-complete clearing at day 56: intent-to-treat population comparing a hydrophilic cream formulation containing tretinoin 0.05%, hydroquinone 4.0%, and fluocinolone acetonide 0.01% (RA+HQ+FA) with the dual-combination agents tretinoin plus hydroquinone (RA+HQ), tretinoin plus fluocinolone acetonide (RA+FA), and hydroquinone plus fluocinolone acetonide (HQ+FA). Asterisk indicates  $P < .001$  vs dual-therapy combinations.



**Figure 3.** African American/Caucasian woman with Fitzpatrick skin type IV and moderate to severe melasma before (A) and after (B) treatment with RA+HQ+FA.

the primary end point was assessed at any time point up to and including week 8, a slightly higher percentage of patients experienced complete clearing (28.6% for RA+HQ+FA vs 10.1% for RA+HQ, 1.9% for RA+FA, and 3.1% for HQ+FA,  $P < .001$ ) (Figure 1). Significantly more of the patients treated with RA+HQ+FA (77%) experienced complete/near-complete clearing compared with each of the dual-therapy groups (42.2% for HQ+FA, 27.3% for RA+FA, and 46.8% for RA+HQ,  $P < .001$ ) (Figure 2). Figures 3 and 4 show representative study patients at baseline and after treatment with the triple-combination therapy.

**Safety**—Adverse events from the pivotal trials of patients treated with the triple combination are summarized in Table 2. Application site erythema, desquamation, burning, dryness, and pruritus were the most frequently occurring adverse events in the RA+HQ+FA treatment group. Only 16 of these adverse events were considered by the investigators to be probably or possibly related to study drugs. No clinically important changes in laboratory parameters were noted.


### Conclusion

Melasma appears to be associated with a number of pathophysiologic factors that change the normal course of pigmentation. These factors include an increased proliferation of melanocytes and an augmented production and facilitated transfer of melanosomes to the basal and suprabasal keratino-

cyte cells.<sup>3,18</sup> The 3 pharmacologic agents assessed in this trial all appear to address various facets of this pathophysiology.<sup>3,15,19-22</sup> The results of this study suggest that these 3 agents used together may be more effective in addressing the pathophysiologic process of melasma than any of the dual-combination agents.

Concern has been raised by researchers about the use of some of these agents or their concentrations. Some researchers have stressed caution in the use of hydroquinone concentrations of 4.0% or higher because of the risk of exogenous ochronosis,<sup>7</sup> a chronic disfiguring condition characterized by reticulated, ripplelike pigmentation of the face.<sup>1</sup> Although the duration of the present study was limited, no instances of ochronosis were observed with any of the treatment regimens containing hydroquinone 4.0%.

Some researchers have discouraged the use of topical corticosteroids as a treatment for melasma because of the risk of skin atrophy and telangiectasia.<sup>7</sup> Kligman et al<sup>16</sup> suggested that subduing the mineralocorticoid effects of glucocorticoids to avoid skin atrophy can be achieved by combining a corticosteroid with a retinoid, such as tretinoin, which abrogates the steroid-induced atrophy. In the present study, only one patient in a dual-therapy group (HQ+FA) developed skin atrophy. The investigators hypothesize that the concomitant use of a retinoid with the steroid may have prevented the development of skin atrophy. Furthermore, the



**Figure 4.** Hispanic woman with Fitzpatrick skin type III and severe melasma before (A) and after (B) treatment with RA+HQ+FA.

Table 2.

**Summary of Treatment-Related Adverse Events at Week 8**

No. Patients With Adverse Event (%)	Treatment			
	RA+HQ+FA (N=161)	RA+HQ (N=158)	RA+FA (N=161)	HQ+FA (N=161)
Erythema	66 (41)	69 (44)	26 (16)	41 (25)
Desquamation	61 (38)	97 (61)	40 (25)	6 (4)
Burning	29 (18)	36 (23)	33 (20)	5 (3)
Dryness	29 (18)	21 (13)	23 (14)	5 (3)
Pruritus	18 (11)	34 (22)	12 (7)	5 (3)
Atrophy	0	0	0	1 (.6)
<b>Total</b>	<b>102 (63)</b>	<b>126 (80)</b>	<b>104 (65)</b>	<b>55 (34)</b>

topical corticosteroid used in this study, fluocinolone acetonide, is a relatively low-potency (class VI) fluorinated corticosteroid. Most instances of telangiectasia were mild and occurred in patients who had this condition before enrolling in the trial.

Overall, the triple-combination product was well tolerated. The most common adverse reactions—erythema, desquamation, burning, dryness, and

pruritus—constitute predictable irritation reactions associated with tretinoin and hydroquinone. Though this study involved use of RA+HQ+FA therapy for 8 weeks, a 12-month, open-label extension trial demonstrated safety and tolerability with long-term use.

In summary, RA+HQ+FA is a formulation using 3 well-established agents for the safe treat-

ment of melasma. When results of the 2 major clinical trials were combined, this formulation was significantly more effective in achieving total clearing of melasma than any of the dual-combination products tested. Additionally, this triple formulation demonstrates favorable safety and tolerability. Due to its ability to address various pathophysiologic factors operative in melasma, as well as to the superior clinical results observed here, triple-combination therapy represents a significant advance in the management of melasma. Avoidance of sun exposure and/or the use of sun block also are necessary for the optimal management of this disorder.

*Acknowledgments*—The authors gratefully acknowledge the technical writing support of Carole Post, PhD, MS, and project coordination by Erica C. Johnson and Diane Hoffman.

## REFERENCES

1. Grimes PE. Melasma: etiologic and therapeutic considerations. *Arch Dermatol*. 1995;131:1453-1457.
2. Mosher DB, Fitzpatrick TB, Ortonne J-P, et al. Hypomelanoses and hypermelanoses. In: Freedberg IM, Eisen AZ, Wolff K, et al, eds. *Fitzpatrick's Dermatology in General Medicine*. Vol 1. New York, NY: McGraw-Hill; 1999:945-1017.
3. Barankin B, Silver SG, Carruthers A. The skin in pregnancy. *J Cut Med Surg*. 2002;6:236-240.
4. Sober AF, Fitzpatrick TB. Disturbances of pigmentation. section I. mechanisms of pigmentation in man. In: Moschella SL, Pillsbury DM, Hurley HJ Jr, eds. *Dermatology*. Vol 2. Philadelphia, Pa: WB Saunders Co; 1975:1085.
5. Vasquez M, Maldonado H, Benmaman C, et al. Melasma in men. *Int J Dermatol*. 1988;27:25-27.
6. Pathak MA, Fitzpatrick TB, Kraus EW. Usefulness of retinoic acid in the treatment of melasma. *J Am Acad Dermatol*. 1986;15:894-899.
7. Giannotti B, Melli MC. Current approaches to the treatment of melasma. *Clin Drug Invest*. 1995;10(suppl 2):57-64.
8. Griffiths CEM, Finkel LJ, Ditre CM, et al. Topical tretinoin (retinoic acid) improves melasma. a vehicle-controlled, clinical trial. *Br J Dermatol*. 1993;129:415-421.
9. Verallo-Rowell VM, Verallo V, Graupe K, et al. Double-blind comparison of azelaic acid and hydroquinone in the treatment of melasma. *Acta Derm Venereol*. 1989;143(suppl):58-61.
10. Sanchez JL, Vazquez M. A hydroquinone solution in the treatment of melasma. *Int J Dermatol*. 1982;20:55-58.
11. Kimbrough-Green CK, Griffiths CEM, Finkel LJ, et al. Topical retinoic acid (tretinoin) for melasma in black patients. *Arch Dermatol*. 1994;130:727-733.
12. Gano SE, Garcia RL. Topical tretinoin, hydroquinone, and betamethasone valerate in the therapy of melasma. *Cutis*. 1979;23:239-241.
13. Kang WH, Chun SC, Lee S. Intermittent therapy for melasma in Asian patients with combined topical agents (retinoic acid, hydroquinone and hydrocortisone): clinical and histological studies. *J Dermatol*. 1998;25:587-596.
14. Katsambas A, Antoniou CH. Melasma: classification and treatment. *J Eur Acad Dermatol Venereol*. 1995;4:217-223.
15. Kligman AM, Willis I. A new formula for depigmenting human skin. *Arch Dermatol*. 1975;111:40-48.
16. Kligman LH, Schwartz E, Lesnik RH, et al. Topical tretinoin prevents corticosteroid-induced atrophy without lessening the anti-inflammatory effect. *Curr Probl Dermatol*. 1993;21:79-88.
17. McMichael AJ, Griffiths CE, Talwar HS, et al. Concurrent application of tretinoin (retinoic acid) partially protects against corticosteroid-induced epidermal atrophy. *Br J Dermatol*. 1996;135:60-64.
18. Sanchez PN, Pathak MA, Sato S, et al. Melasma: a clinical, light microscopic, ultrastructural, and immunofluorescence study. *J Am Acad Dermatol*. 1981;4:698-710.
19. Denton CR, Lerner AB, Fitzpatrick TB. Inhibition of melanin formation by chemical agents. *J Invest Dermatol*. 1952;18:119-135.
20. Jimbow K, Obata H, Pathak MA, et al. Mechanism of depigmentation by hydroquinone. *J Invest Dermatol*. 1974;62:436-449.
21. Penney KB, Smith CJ, Allen JC, et al. Depigmenting action of hydroquinone depends on disruption of fundamental cell processes. *J Invest Dermatol*. 1984;82:308-310.
22. Craven NM, Griffiths CE. Topical retinoids and cutaneous biology. *Clin Exp Dermatol*. 1996;21:1-10.